

The Pediatric Airway

A Quick Review

The Pediatric Airway

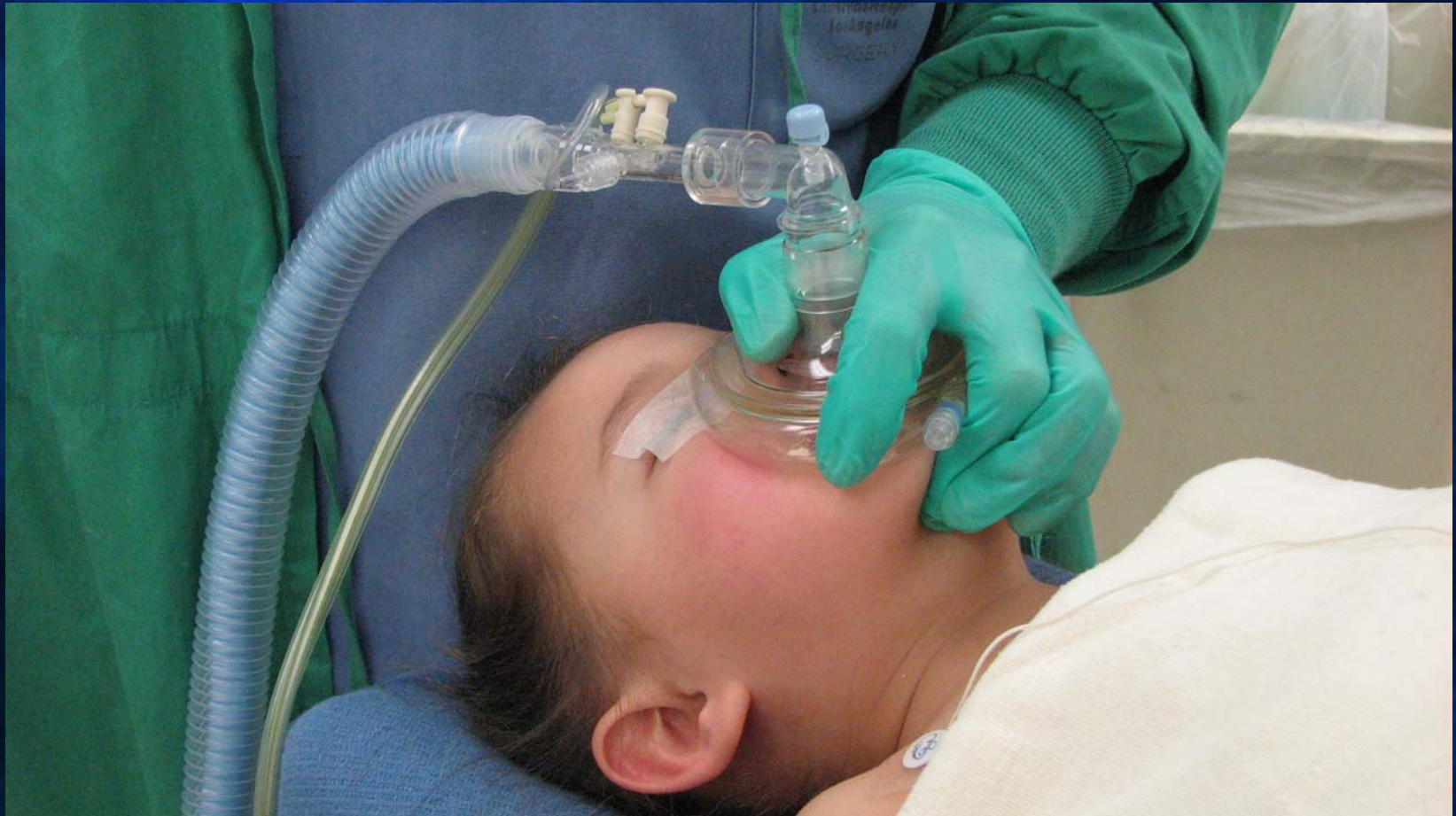- ★ Larger occiput; short neck
- ★ Relatively large tongue
- ★ Potential for loose teeth
- ★ Small nasal and airway passages
- ★ Enlarged tonsillar and adenoidal tissue

The Pediatric Airway cont.

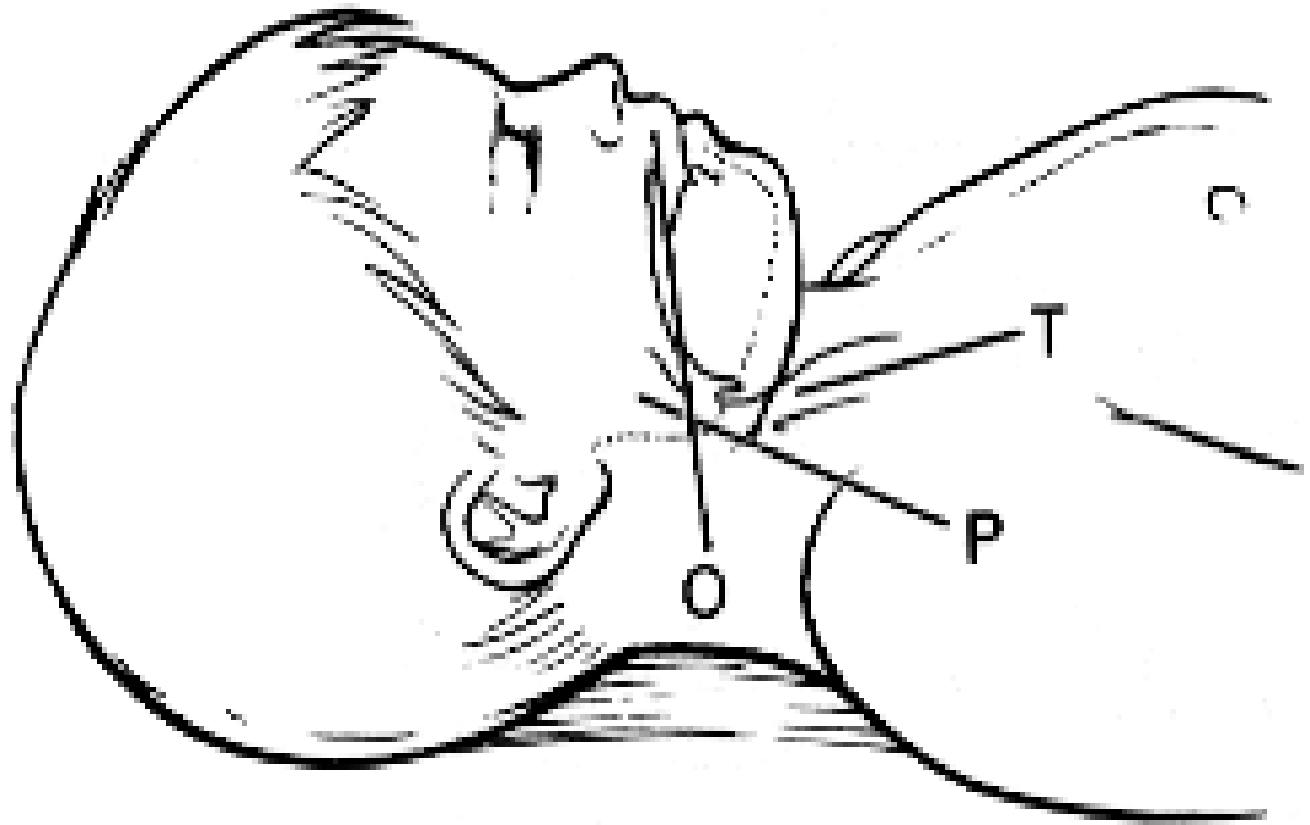
- ★ Narrow short epiglottis angled into lumen of the airway
- ★ Cephalad anterior larynx (C₂₋₃)
- ★ Airway narrowest at cricoid cartilage
- ★ Short trachea
- ★ Decreased structural elasticity

Pediatric Airway Pearls

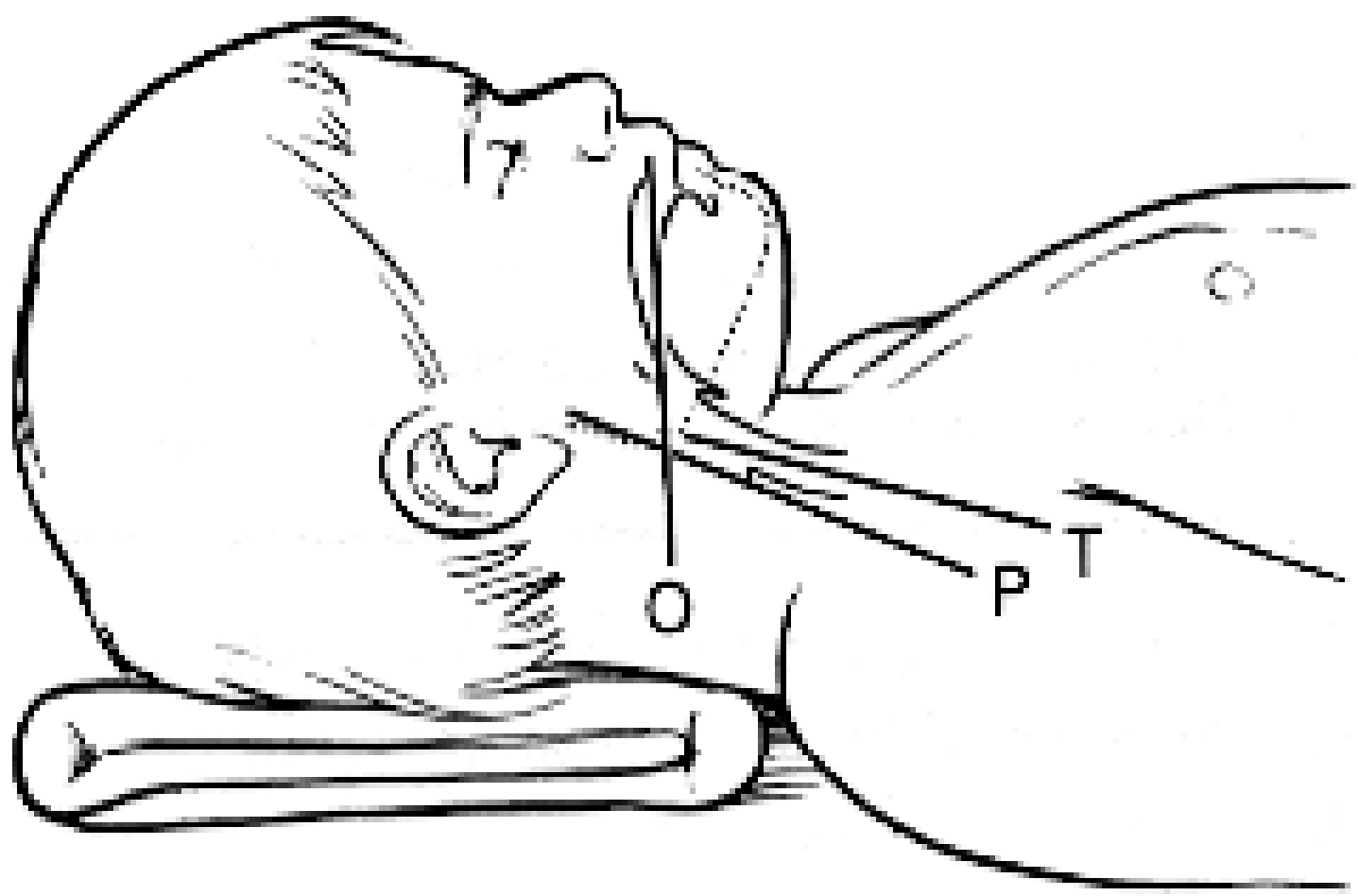
- ★ Proper holding of the mask
- ★ Alignment of oral, pharyngeal and tracheal axes
- ★ Proper size and use of equipment
- ★ Increased airway sensitivity
- ★ Proper size and placement of nasal and oral airways
- ★ **Less is better!!!!**



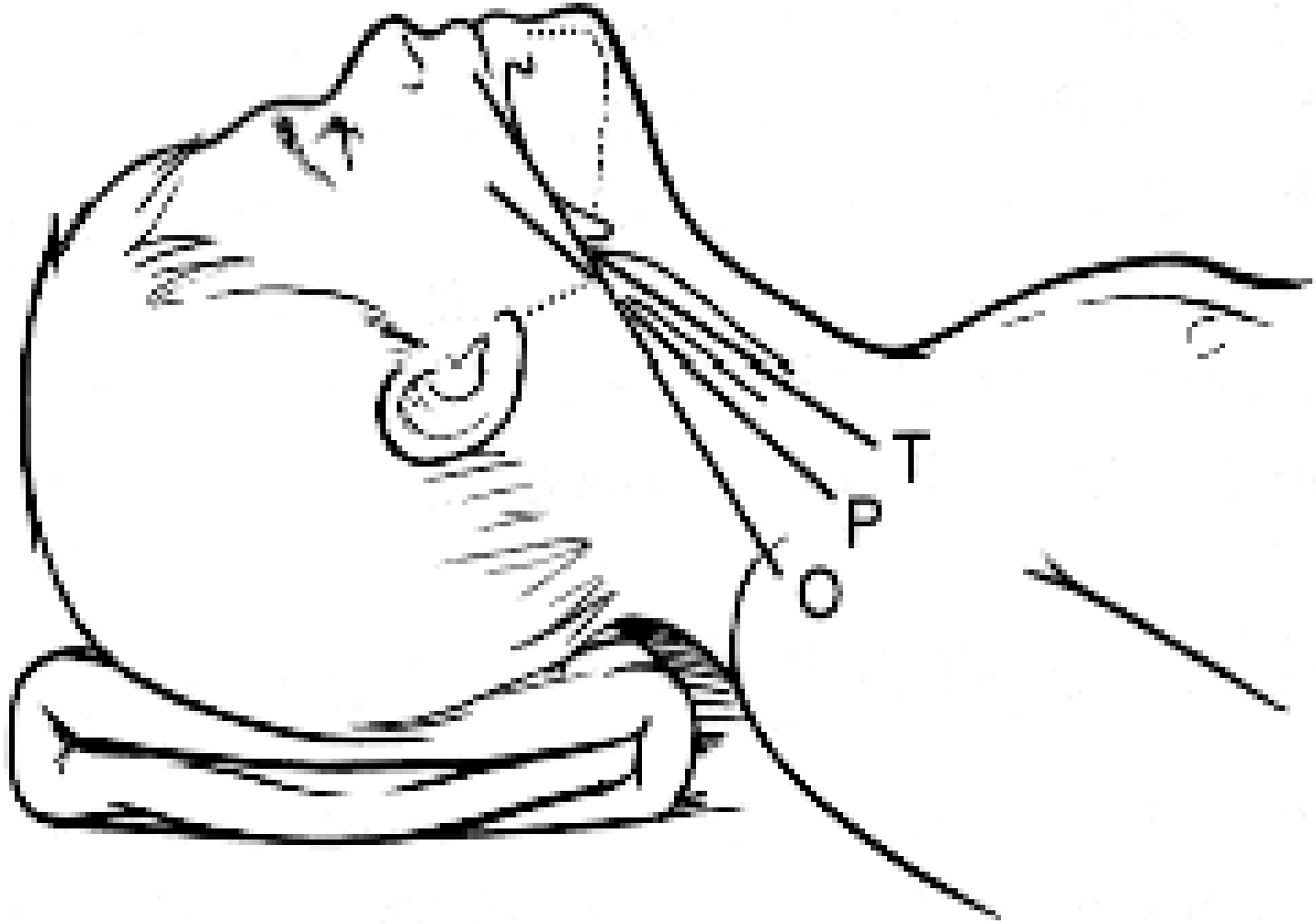
A

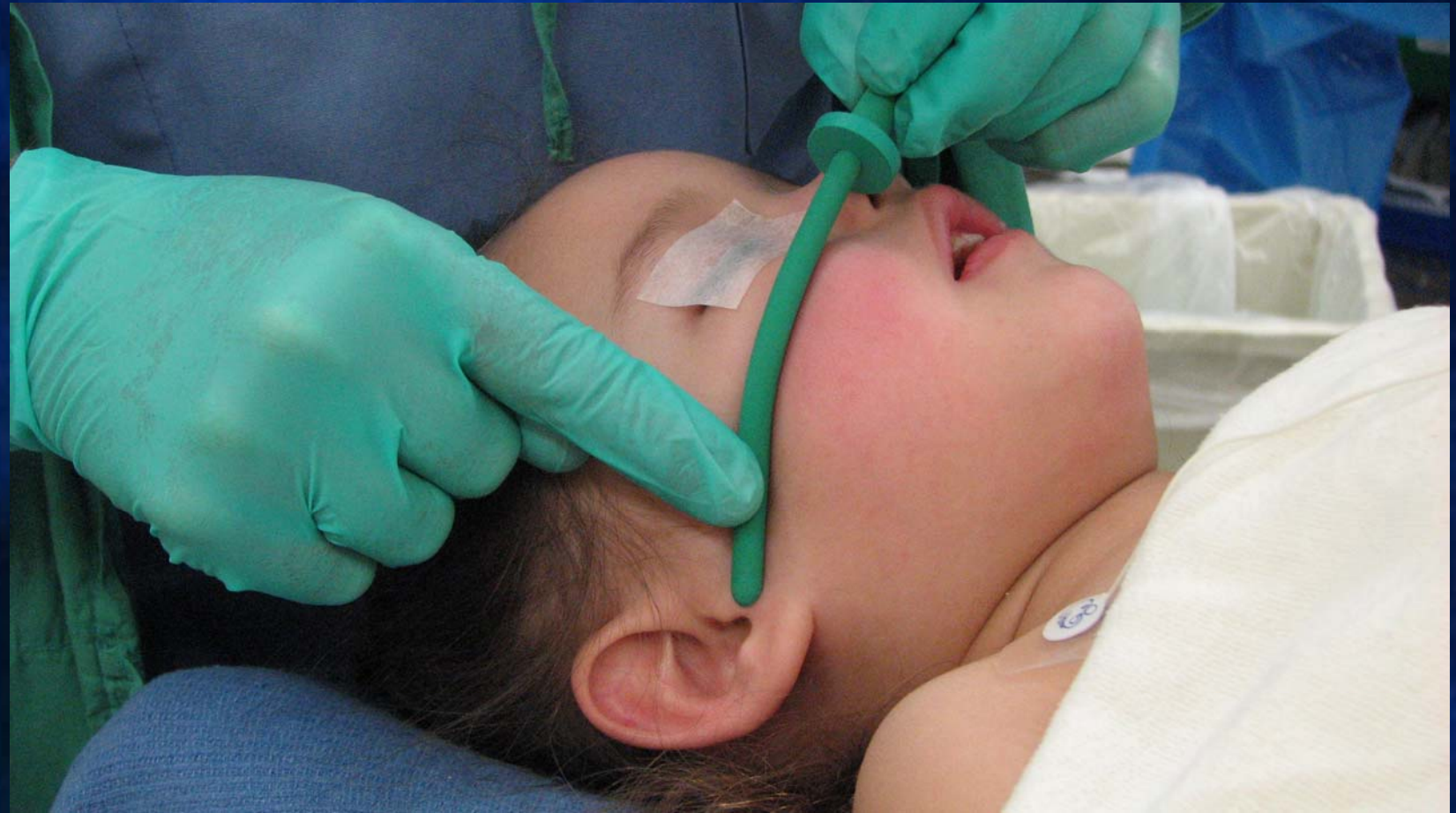

B

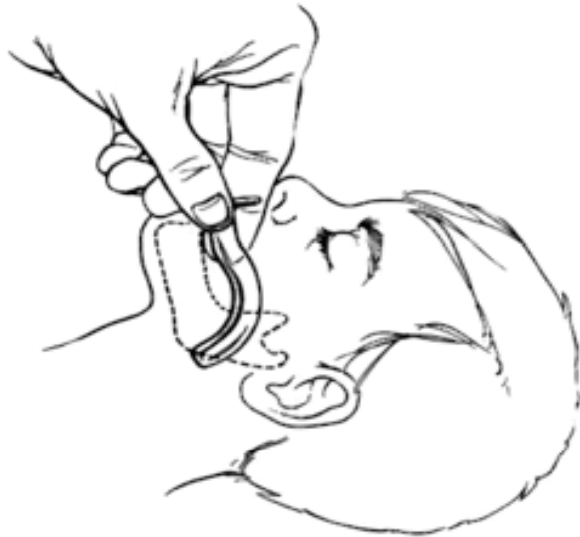

C

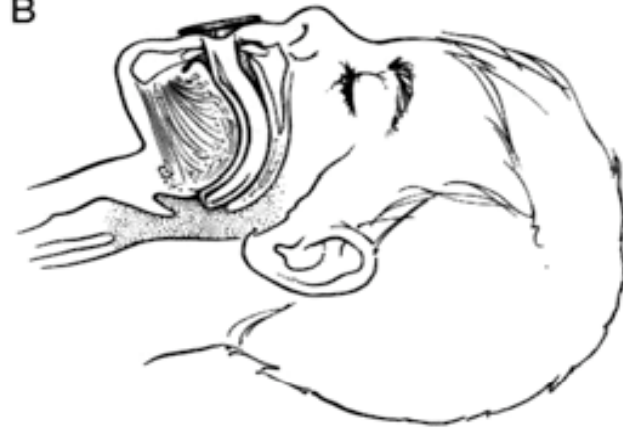



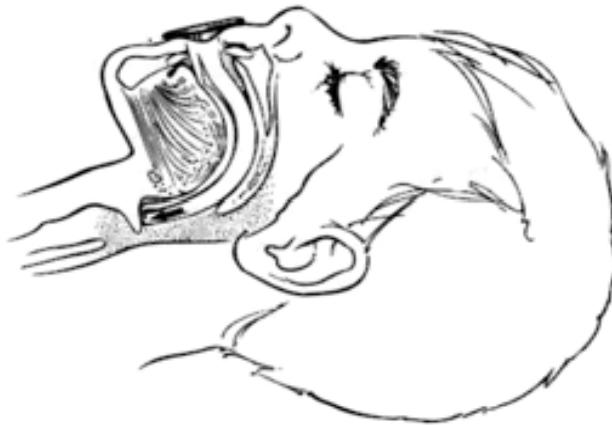A



B



C



D

